

LIGAMENTOTAXOR®

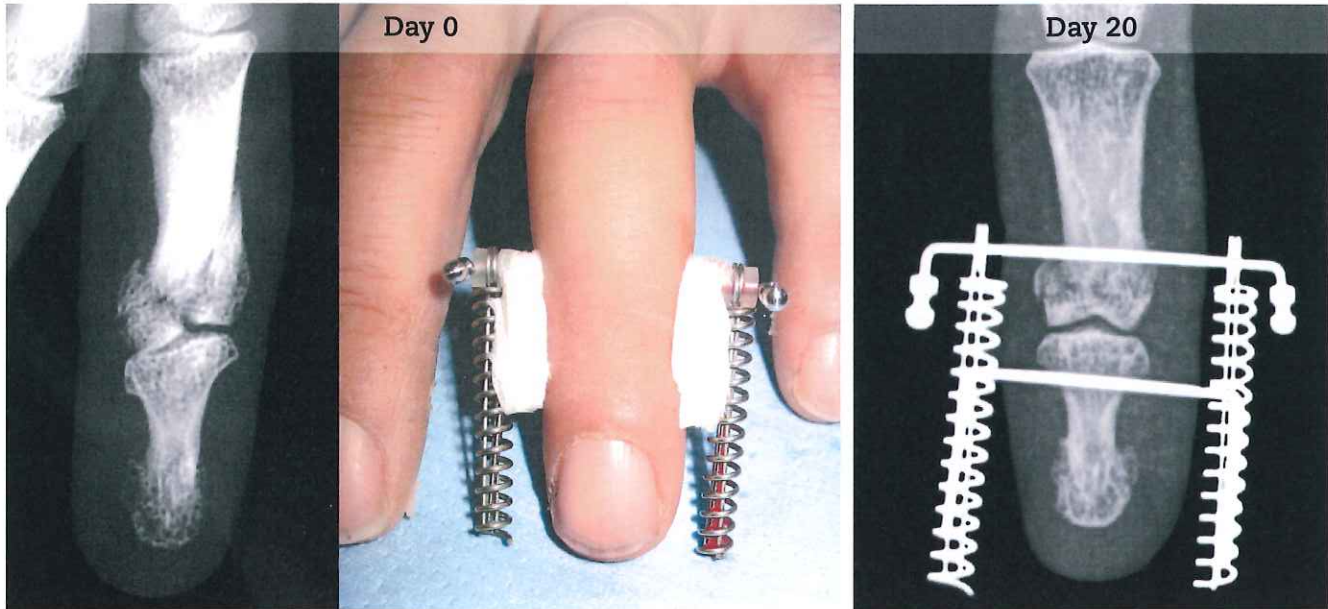
Clinical case, Prof. Ph. Pélissier - Bordeaux CHU, France

Male - 32 years
Fracture DIP 4th finger, left hand.

J.B. Implants Services bv

Robijnborch 7
5241 LK Rosmalen
www.jb-implants.nl

T 073 52 20780
F 073 52 21245
E jblock@knoware.nl

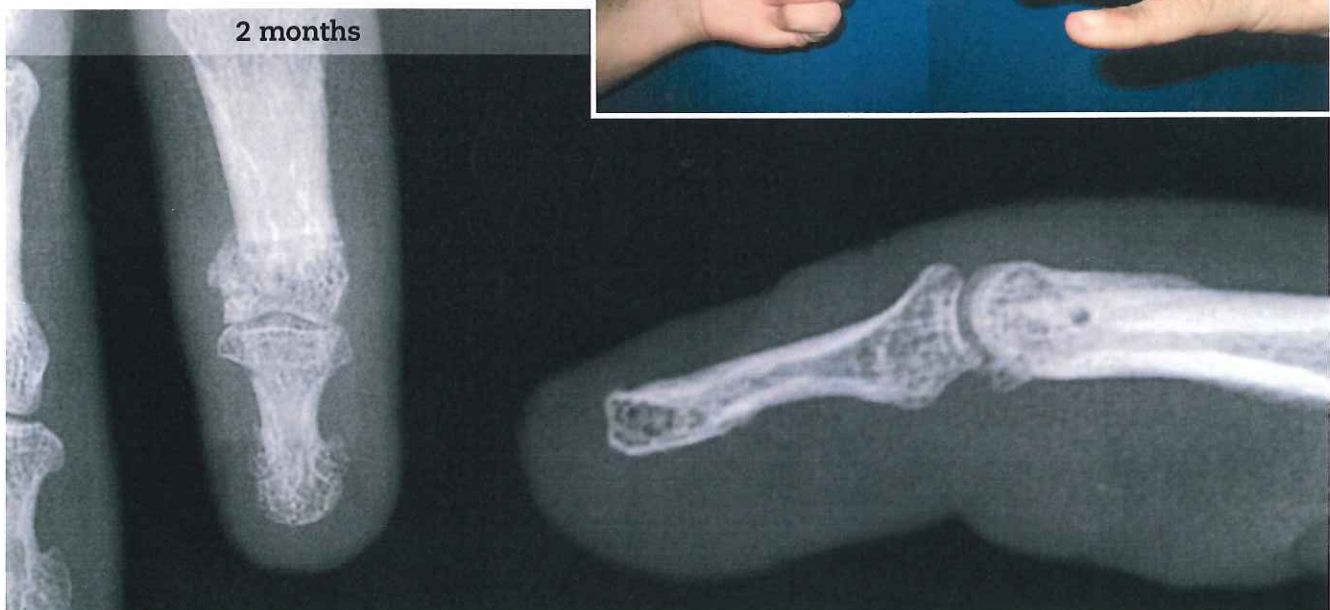

POST OPERATIVE

Rehabilitation protocol:

D0 - D10 Articular traction, no mobilisation.
D10 - D25 Passive mobilisation.
D25 - D40 Active mobilisation.
D40 Apparatus is removed.

Results after 2 months:

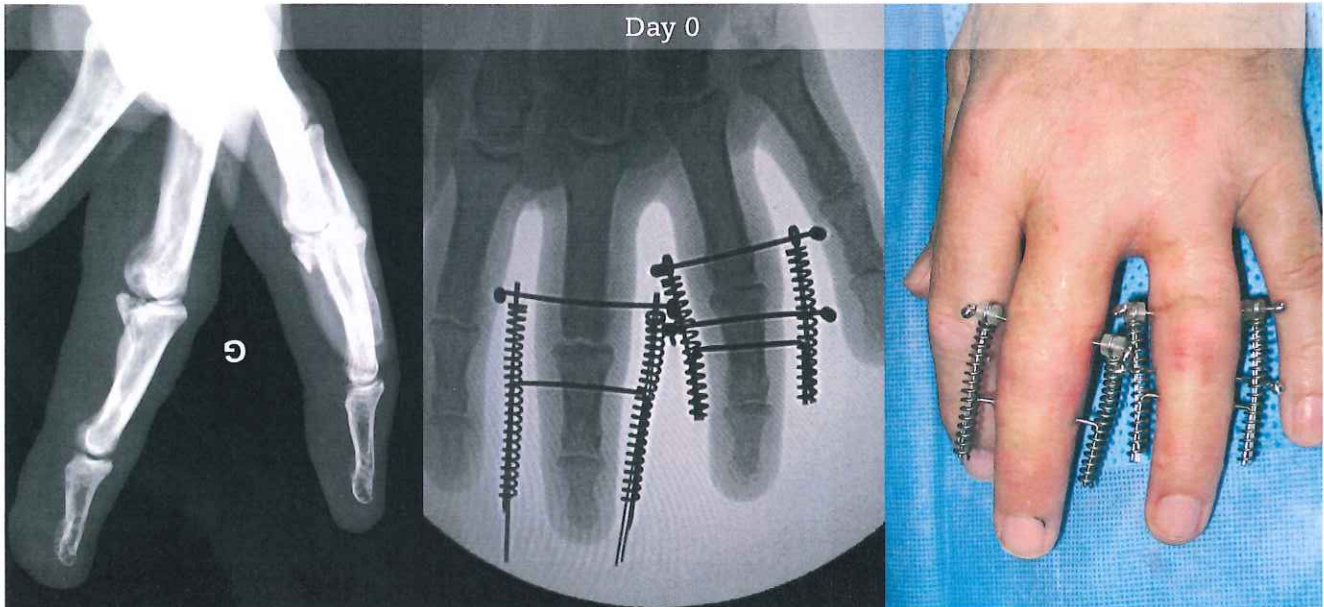


LIGAMENTOTAXOR®

Clinical case, Prof. Ph. Pélissier - Bordeaux CHU, France

Male - 54 years

Crush fracture of proximal interphalangeal (PIP) joints, 3rd and 4th fingers.



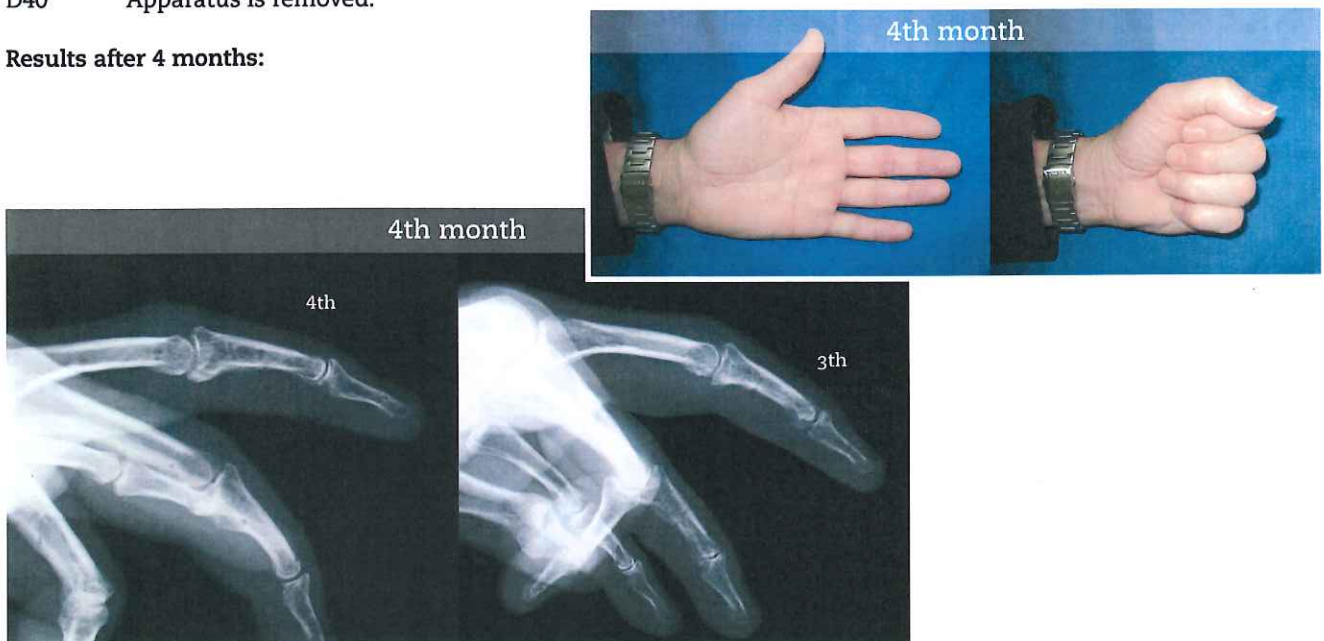On 3rd finger, articular traction with LIGAMENTOTAXOR® to reduce fracture.
On 4th finger, initial posterior displacement at the base of P2 is reduced by a supplementary transverse pin supported by lateral bars.

POST OPERATIVE

Rehabilitation protocol:

- D00 - D10 Articular traction, no mobilisation.
- D10 - D25 Passive mobilisation.
- D25 - D40 Active mobilisation.
- D40 Apparatus is removed.

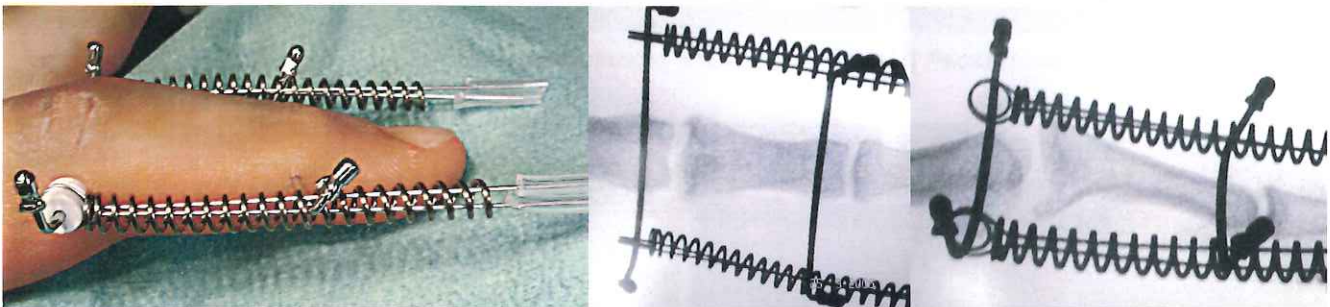
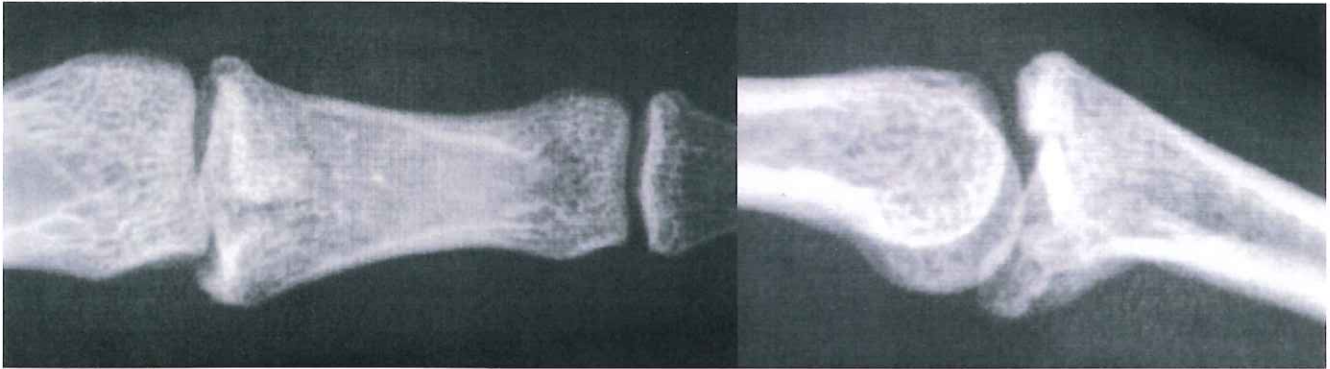
Results after 4 months:



LIGAMENTOTAXOR®

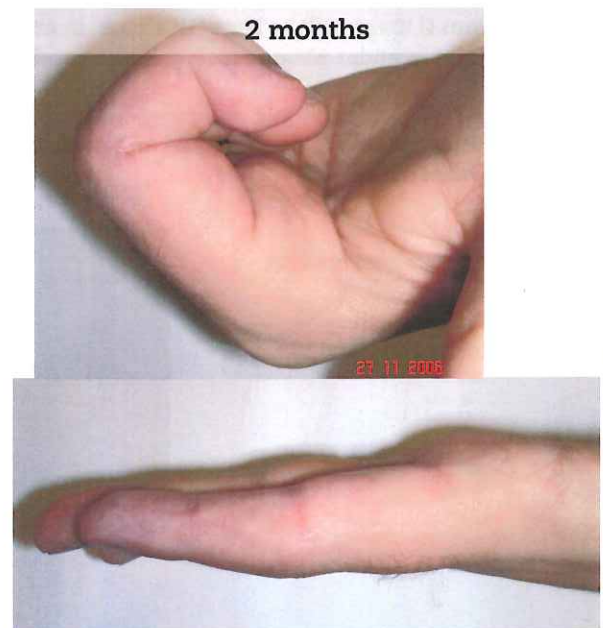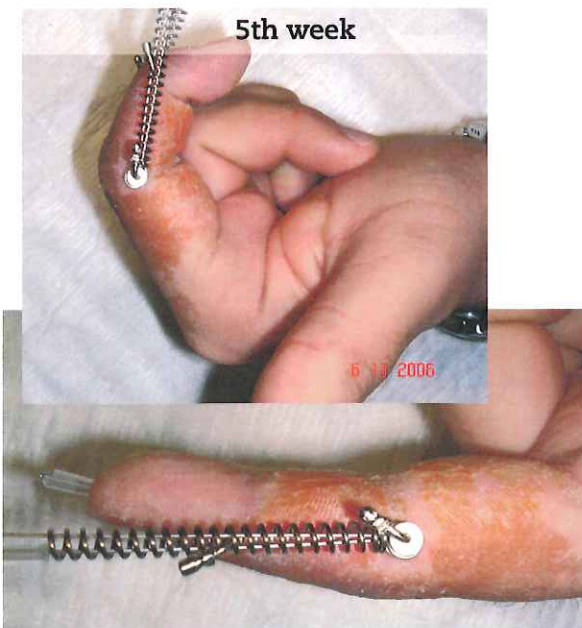Clinical case, Prof. M. Merle - Hôpital de Kirchberg, Luxembourg

Male - 18 years
Fracture at base of index P2, left hand.



The proximal pin must be positioned in strict alignment with the PIP joint axis of rotation.
Distraction is adjusted to achieve optimal remodelling of base of P2.

POST OPERATIVE



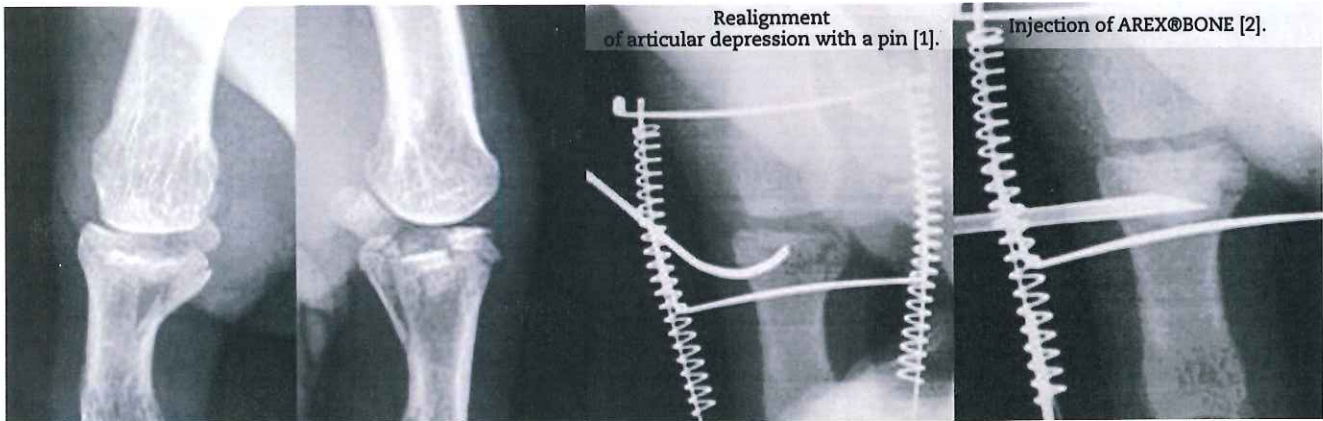
Création : e-moncaux / Réf. 114 ed.03 - © AREX® - 2010

LIGAMENTOTAXOR[®]

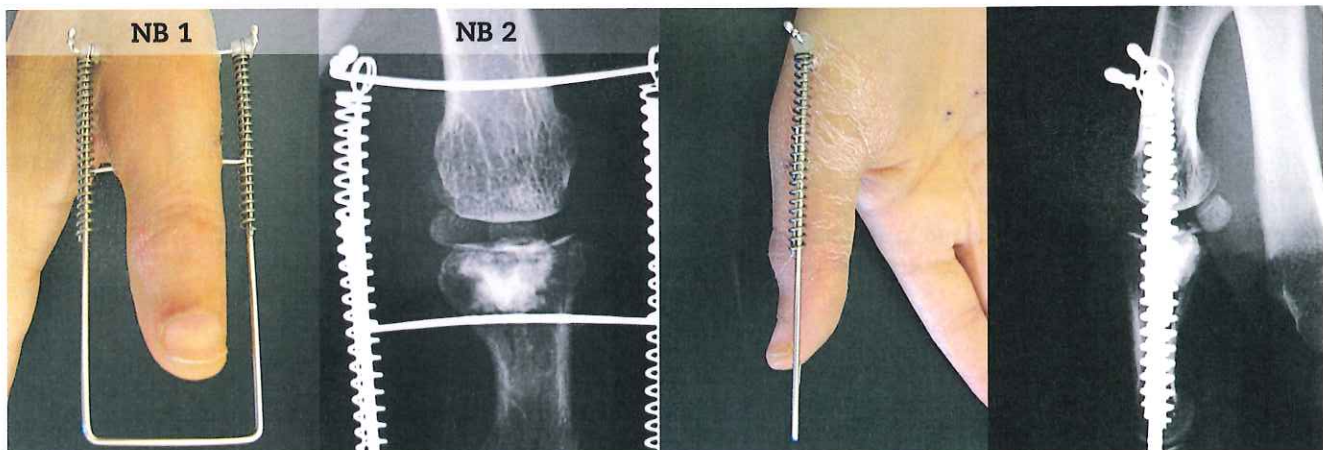
Clinical case, Prof. Ph. Liverneaux - SOS MAIN Strasbourg Hôpitaux Universitaires, France

Male - 47 years

Fracture at base of first phalanx of thumb, right hand.



D0: Application of LIGAMENTOTAXOR[®]. [1] & [2] percutaneous procedure throughout.



NB 1: 1.5 mm Ø Kwire will be bent "U" shape in order to realise a stabilizing frame.

NB 2: MP joint is under strong tension, Kwires and springs are curved.

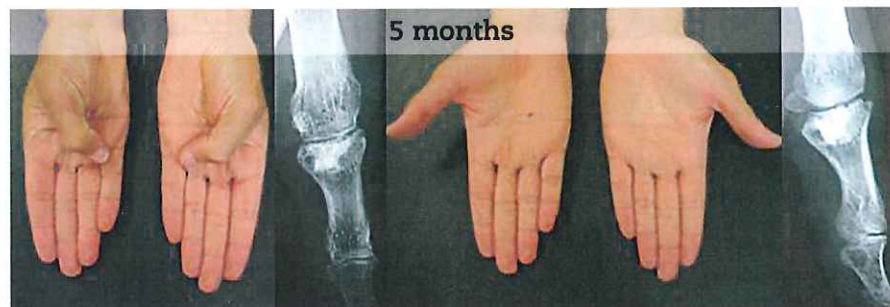POST OPERATIVE

D1 The patient is able to use his hand and even write. (see video on website)

D30 Removal of splint.

At 5 months, excellent results:

- No pain.
- Mobility and strength identical to contralateral hand.



LIGAMENTOTAXOR®

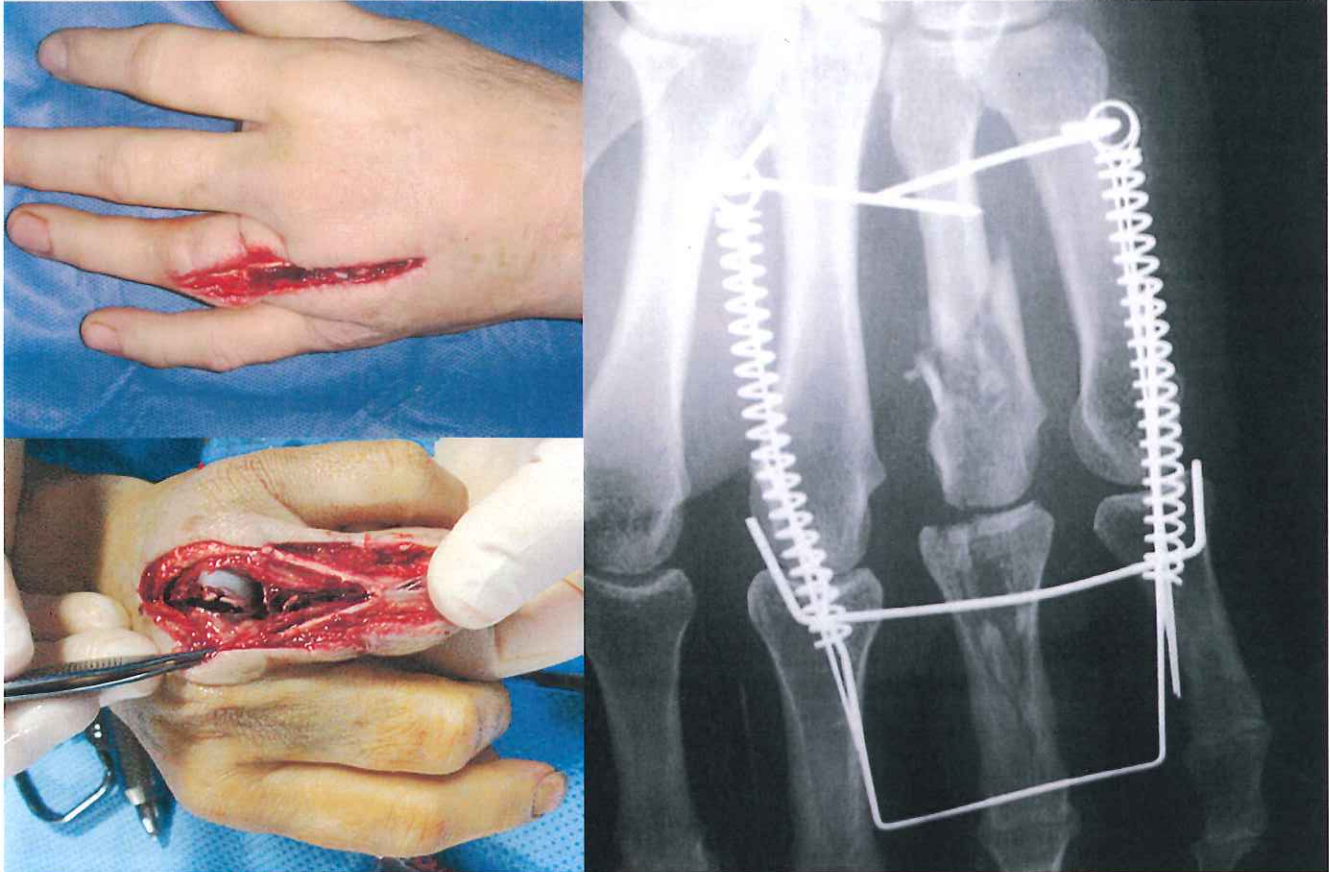
Clinical case, M. Schoofs, MD - Lille, France

Woman - 44 years

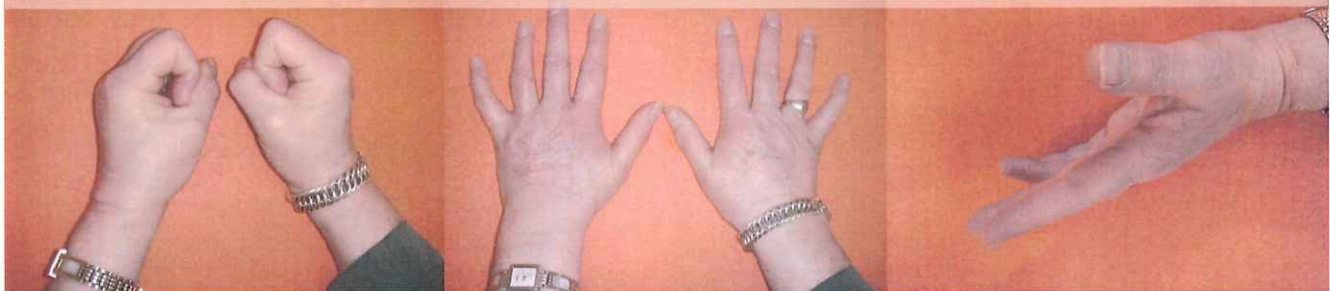
Dorsal wound to left hand caused by lawnmower blade, 4th digit involvement.

Fracture of 4th metacarpal and 1st phalanx.

Comminuted multifragmentary fracture and extensor dilaceration extending to PIP joint, including metacarpo-phalangeal capsule.



Video at 6 months on the web site : WWW.AREX.FR



Création : e-monceaux / Réf. 114 ed.03 - © AREX® - 2010

LIGAMENTOTAXOR[®]

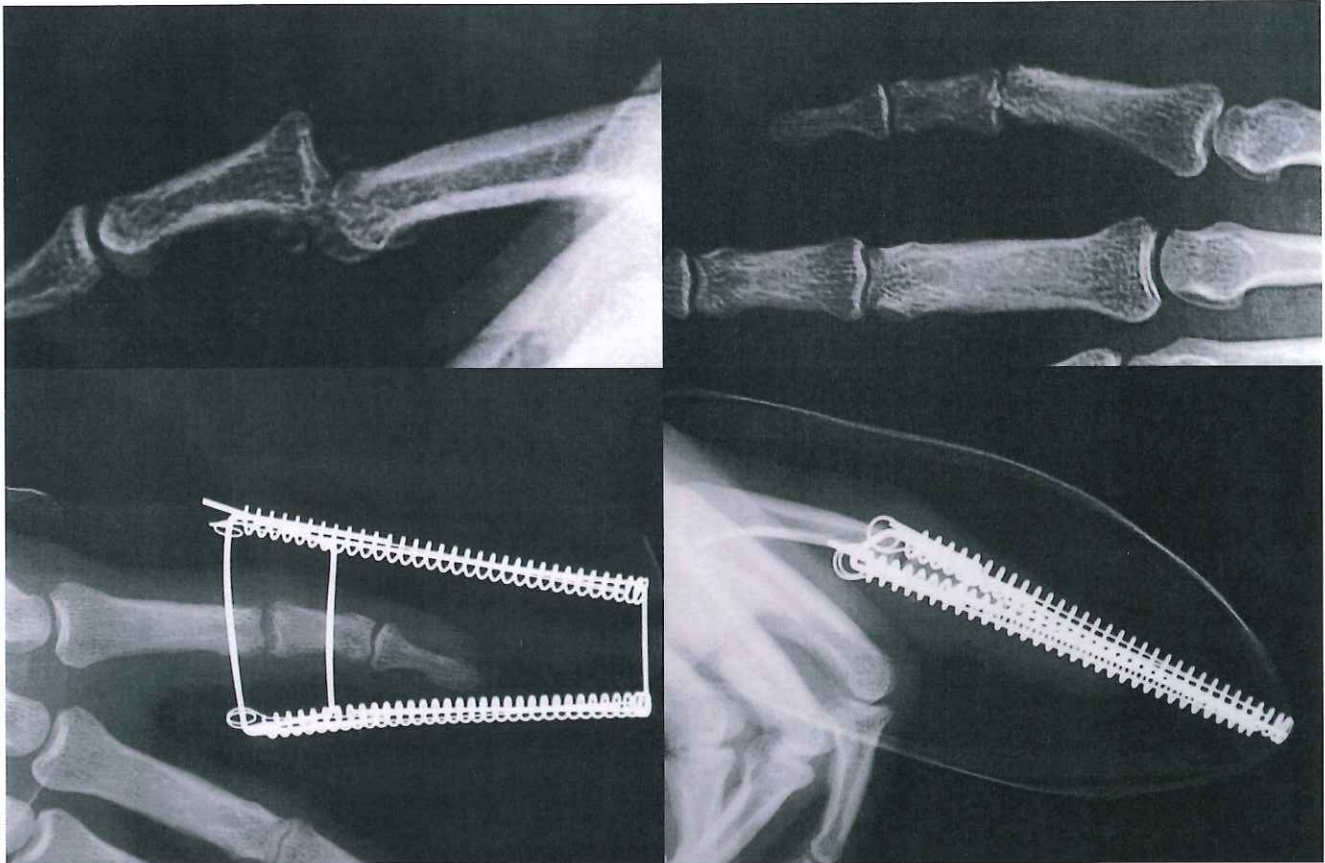
Clinical case, M. Schoofs, MD - Lille, France

Man - 30 years

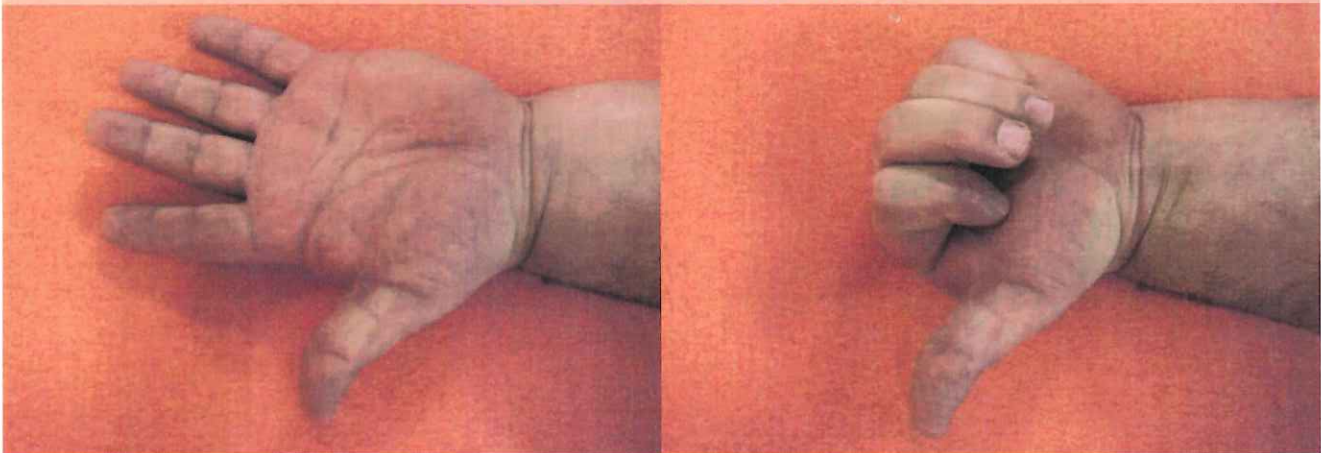
Irreducible, one month old luxation of PIP joint, 5th digit of right hand

Seen September 9, 2009. Operated on September 12, 2009 with placement of Ligamentotaxor.

Removed on November 4, 2009.



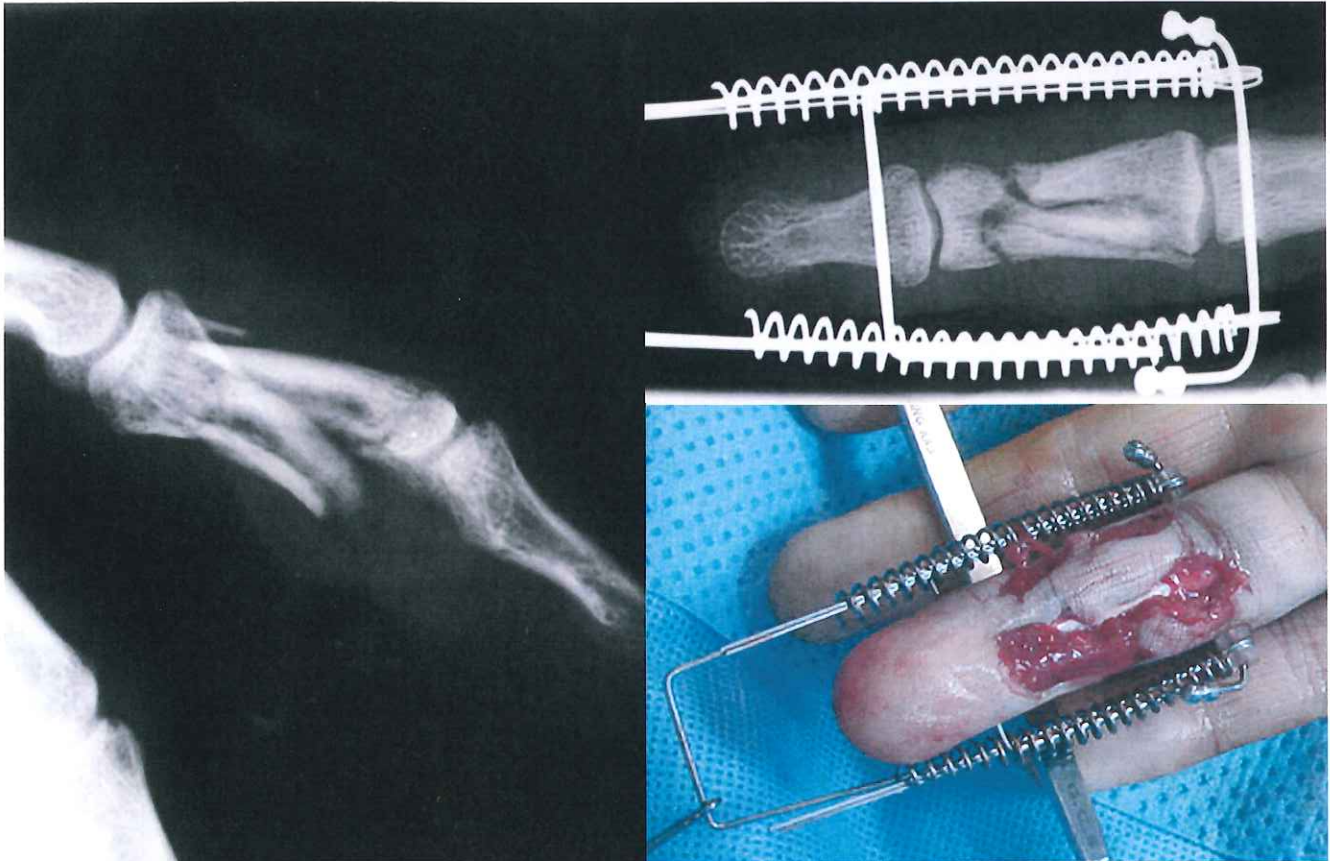
Video at 2 months. Visible on WWW.AREX.FR site.



LIGAMENTOTAXOR®

Clinical case, M. Schoofs, MD - Lille, France

Man - 35 year
with open crush injury to phalanx P2 and severe cutaneous contusion and tissue loss.
No severance of flexor tendon.
Treatment: resection, partial suture, placement of Ligamentotaxor® and managed wound care.



Video at 8 weeks, post initial traumatic event. Visible on WWW.AREX.FR site.

