



ADCON-L and hypotension during lumbar microdiscectomy

S. Kalogrianitis¹, P. Barrett² and I. Shackelford²

+ Author Affiliations

Abstract

ADCON-L anti-adhesion gel is used as an antifibrotic agent in surgery for herniated lumbar disc. We report seven patients undergoing lumbar microdiscectomy, in whom ADCON-L gel was applied to the nerve root before closure of the surgical site. After the administration of ADCON-L, tachycardia and hypotension were noted, and were quickly and effectively reversed by i.v. fluids and ephedrine. Since its routine introduction into our practice, we have given ADCON-L on 212 occasions, with an incidence of adverse haemodynamic reactions of 3.3%. Adverse cardiovascular reactions do not appear to have been reported before.

Br J Anaesth 2001; **87**: 770-1

Key words Keywords: antifibrotic agent, ADCON-L anti-adhesion gel; complications, tachycardia; complications, hypotension

Accepted for publication: June 28, 2001

ADCON-L (Gliatech, Cleveland, OH, USA) is a bioresorbable gel that provides a mechanical barrier that inhibits fibroblast migration on and around the neural structures. It consists of a polyglycan ester and absorbable pig-derived gelatin in phosphate-buffered saline. It is applied to the dura and nerve roots during surgery to prevent scar and adhesion formation. The scientific rationale for ADCON-L is based on properties of glial cells and the nature and role of the basal lamina. ¹ ADCON-L is used in intraspinal lumbar surgical procedures as a temporary physical barrier to minimize post-operative peridural fibrosis, adhesions and subsequent clinical sequelae. ² In both the USA and Europe, ADCON-L is designated a medical device and not a drug.

Methods and results

We report seven patients aged between 31 and 55 yr (four female and three male, mean age 42 yr) and ASA status 1, who received ADCON-L during first-time unilateral, single-level lumbar microdiscectomy. All patients received a standard anaesthetic consisting of induction with propofol, relaxation with vecuronium, and maintenance with nitrous oxide, oxygen and sevoflurane. Incremental doses of vecuronium were used to maintain paralysis. Patients were ventilated to maintain normocapnia and normoxia and anaesthesia was adjusted to maintain normal cardiovascular variables. Patients were placed in the knee-elbow position and a similar microsurgical procedure was performed in all cases via a paramidline approach. All procedures were uneventful and there was no evidence of dural tear. At completion of the surgical procedure, the surgical site was irrigated thoroughly and immaculate haemostasis was achieved. Before closure of the surgical site, ADCON-L gel 5 g was applied, covering all accessible surfaces of the nerve root, including the radicular foramen, between the dural sac and the posterior longitudinal ligament and between the dorsal surface of the dural sac and overlying muscle up to the level of the anterior surface of the lamina. Within seconds after the administration of ADCON-L, tachycardia and hypotension became apparent.

The mean (SEM) systolic pressure before the administration of ADCON-L was 108 (4), and after the application of ADCON-L it decreased to 80 (4). Similarly, the heart rate before ADCON-L was 65 (3) beats min⁻¹ and after ADCON-L it increased to 94 (7) beats min⁻¹ (Fig. 1). Hypotension was restored to the pre-induction level within an average of 8.7 min (range 3-15 min) after the administration of i.v. fluids (Hartman's solution, mean volume 1000 ml, and Gelofusine, mean volume 500 ml) and ephedrine 12-15 mg given incrementally. None of these hypotensive episodes was associated with hypoxaemia and the ECG showed sinus tachycardia throughout. No patient developed bronchospasm, urticaria or erythema and there was no increase in body temperature. After cardiovascular stability had been restored, a blood sample was obtained and serum tryptase (an indicator of mast cell degranulation and therefore histamine release) was measured. ³ Serum

tryptase was not identified in any of the patients. All patients remained stable post-operatively and were discharged the next day after an uneventful recovery.

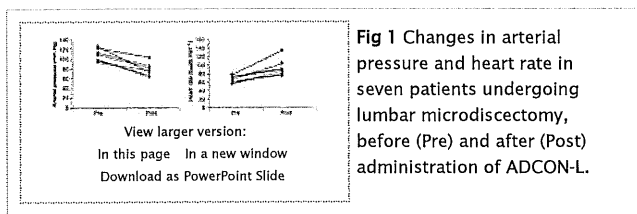


Fig 1 Changes in arterial pressure and heart rate in seven patients undergoing lumbar microdiscectomy, before (Pre) and after (Post) administration of ADCON-L.

Discussion

Since its routine introduction into our practice, we have given ADCON-L on 212 occasions and it has led to adverse haemodynamic effects in seven cases. No side-effects have been noted in the last 100 consecutive cases.

Mechanisms that may account for ADCON-L-induced cardiovascular instability include anaphylactic reaction, direct myocardial depression and systemic vasodilatation. Anaphylactic reaction is unlikely because other systemic manifestations of allergy, such as erythema, urticaria, salivation, cyanosis or bronchospasm, were absent. In addition, serum tryptase was not identified in any of the cases.

Myocardial depression and systemic vasodilatation may have occurred secondarily to the systemic absorption of ADCON-L, although, because this substance is used as an implant and not as a drug, it has not been investigated to determine if it has vasoactive properties. However, i.v. fluids and vasopressors were required in moderate doses in order to treat the haemodynamic changes. Intravenous fluids improve myocardial contractility by improving cardiac preload, and they also reverse the haemodynamic effects of a vasodilated circulation. Ephedrine has chronotropic, inotropic and vasoconstrictor properties and therefore directly improves myocardial contractility and reverses systemic vasodilatation. Heart rate decreased and blood pressure increased after the administration of i.v. fluid and ephedrine, and we propose that the mechanism of the observed haemodynamic changes is myocardial depression and systemic vasodilatation. The reactions are similar to those described after the use of methylmethacrylate cement, which is used to fix orthopaedic prostheses. In these instances, a transient fall in blood pressure within 1 or 2 min of inserting the methylmethacrylate cement into the medullary canal of the femur is often observed. Usually, arterial pressure returns to normal in 3–5 min. The adverse effects of methylmethacrylate include systemic vasodilatation and direct myocardial depression secondary to absorption of the methylmethacrylate cement.^{4–6} Embolism of fat, air or bone marrow can occur when methylmethacrylate cement is used, but there is no reason to believe that these may have occurred after the administration of ADCON-L.

There are important implications for the anaesthetist whenever ADCON-L is used. We now routinely administer Hartman's solution 1000 ml and Gelofusine 500 ml during surgery and before ADCON-L is administered. In more than 100 consecutive microdiscectomies, no episodes of hypotension have been observed since this practice was introduced.

References

- 1 Frederickson RC. ADCON-L: a review of its development, mechanism of action, and preclinical data. *Eur Spine J* 1996; 5 (Suppl 1): 7–9
- 2 de Tribolet N, Porchet F, Lutz TW, *et al*. Clinical assessment of a novel antiadhesion barrier gel: prospective, randomized, multicenter, clinical trial of ADCON-L to inhibit postoperative peridural fibrosis and related symptoms after lumbar discectomy. *Am J Orthop* 1998; 27: 111–20
- 3 Fisher M, Baldo B. Mast cell tryptase in anaesthetic anaphylactoid reactions. *Br J Anaesth* 1998; 80: 26–9
Abstract/FREE Full Text
- 4 Karisson J, Wendling W, Chen D, *et al*. Methylmethacrylate monomer produces direct relaxation of vascular smooth muscle *in vitro*. *Acta Anaesthesiol Scand* 1995; 39: 685–9
Medline Web of Science
- 5 Pinto PW Cardiovascular collapse associated with the use of methylmethacrylate. *AANA J* 1993; 61: 613–6
Medline
- 6 Spiess BD, Sloan MS, McCafferty RJ, *et al*. The incidence of venous air embolism during total hip arthroplasty. *J Clin Anesth* 1988; 1: 25–30
CrossRef Medline