


Treatment of fracture subluxations of the proximal interphalangeal joint using a ligamentotaxis device: a multidisciplinary approach

The Journal of Hand Surgery
(European Volume)
XXE(X) 1–7
© The Author(s) 2015
Reprints and permissions:
sagepub.co.uk/journalsPermissions.nav
DOI: 10.1177/1753193415578305
jhs.sagepub.com


R. J. MacFarlane, S. Gillespie, F. Cashin, A. Mahmood,
G. Cheung and D. J. Brown

Abstract

Complex fracture subluxations of the proximal interphalangeal joint are often difficult to treat and their outcome variable. A number of methods for treatment of these injuries have been described. We have used a ligamentotaxis device (*Ligamentotaxor*, Arex, Palaiseau Cedex, France) since 2008. We performed 28 operations in 28 patients with complex proximal interphalangeal joint injuries over a 3-year period. Patients followed a standardized postoperative rehabilitation regime, including fixator adjustment as necessary. The mean age was 33 years (range 18–67). The mean time to surgery was 7 days. At final follow-up (mean 22 months, range 6–52) the mean proximal interphalangeal joint range of motion was 85° (range 60°–110°). The mean QuickDASH functional outcome score was 4.8 (range 0–36.4). Our results compare favourably with other devices reported in the literature.

Keywords

Ligamentotaxis, proximal interphalangeal joint, fracture, subluxation, multidisciplinary

Date received: 12th June 2012; revised: 17th February 2015; accepted: 28th February 2015

Introduction

Complex injuries involving the proximal interphalangeal joint (PIPJ) are often difficult to treat and variable in their outcome. A range of techniques have been described for fixation of these injuries, including closed reduction and temporary Kirschner-wire fixation (Newington et al., 2001), open reduction and internal fixation (Grant et al., 2005), and a number of devices providing dynamic external fixation (Allison, 1996; De Soras et al., 1997; Ellis et al., 2007; Fahmy, 1990; Hynes and Giddins, 2001; Johnson et al., 2004; Suzuki et al., 1994; Syed et al., 2003).

Techniques that involve immobilization of the PIPJ often result in a limited range of motion (ROM) or functional deficit. Stable reduction of the subluxed or dislocated PIPJ, sufficient to allow early mobilization, has been the goal of treatment in recent years; the outcomes of various dynamic external fixation devices are being reported, but with variable results (Deitch et al., 1999; Körting et al., 2009; Majumder et al., 2003).

Fracture-dislocations of the PIPJ have been classified by several authors (Seno et al., 1997; Syed et al.,

2003). These systems describe the site and the fracture and degree of articular involvement. In general, the degree of subluxation/dislocation at the PIPJ increases in proportion to the degree of volar articular surface involvement. Pilon type fractures of the PIPJ may result in comminution, central depression, and sagittal or coronal splay of the articular surface of the base of the middle phalanx (Syed et al., 2003). According to the classification by Seno et al. (1997), type 1 injuries represent volar-sided fractures of the base of the middle phalanx, with associated dorsal subluxation, and type 2 injuries represent those with a dorsal fracture of the middle phalanx and associated

Liverpool Upper Limb Unit, Royal Liverpool University Hospital,
Liverpool, UK

Corresponding author:

R. J. MacFarlane, Department of Orthopaedics, Royal Liverpool
University Hospital, Prescot Street, Liverpool L7 8XP, UK.
Email: robert.macfarlane@doctors.org.uk

Table 1. Physiotherapy and occupational therapy input.

<ul style="list-style-type: none"> • Active and passive physiological movements to the affected joint and adjacent joints • Active and passive composite flexion and extension within the limits of pain • Blocking manoeuvres to improve the isolated flexion of the finger joints • Tendon gliding exercises • Home exercise programme of active and assisted flexion/extension movements • Pinsite care • Desensitization techniques as necessary • Static night splintage is routinely used to prevent PIPJ contracture and to avoid patient knocking hand at night <p>Therapy goals during first 6 weeks:</p> <ul style="list-style-type: none"> • Week 1: Reinforce exercises and pinsite care. Radiographic check and adjust spring tension in outpatients dependent on position. Passive motion up to 90° • Week 2: Assess progress and technique. Radiographic check in some patients. Active motion to 60°–90°. Spring tension adjustment. Splintage as necessary to prevent extension lag • Week 4: Radiographic check and adjust as necessary. Active and passive motion aiming for 90° • Week 6: Radiographic check. Device removal if clinical and radiographic progress satisfactory. Active and passive motion beyond 90° where possible
--

PIPJ: proximal interphalangeal joint.

volar subluxation. Both type 1 and type 2 injuries are subdivided into subtypes a, b, and c, indicating the severity of the fracture (avulsion fracture, partial articular coronal split, and split depression, respectively). In addition to types 1 and 2, type 3 injuries represent sagittal plane fractures of the middle phalanx, type 4 injuries represent physeal injuries in children, and type 5 represent both dorsal and volar articular involvement (Syed et al., 2003). External fixation with a device providing dynamic traction is indicated for intra-articular fractures involving the PIPJ, combined with either subluxation or dislocation of the joint.

The *Ligamentotaxor* (Arex, Palaiseau Cedex, France) has been in use in our institution since 2008. The device provides traction across the PIPJ and facilitates reduction of PIPJ subluxations and maintains the positioning of displaced fracture fragments by 'ligamentotaxis' while allowing good PIPJ movement.

The aim of this study was to present the results of a series of patients with fracture-subluxations involving the PIPJ treated with the *Ligamentotaxor* and a standardized postoperative rehabilitation regime.

Methods

A prospective review was performed of patients with fracture-subluxations of the PIPJ treated with a *Ligamentotaxor* device. All patients referred to the hand trauma clinic at the Liverpool Upper Limb Unit, Royal Liverpool University Hospital, between October 2008 and June 2011, with an acute fracture subluxation or dislocation involving the PIPJ, were considered for inclusion. Patients with avulsion fractures of the PIPJ with associated subluxations were treated conservatively with closed reduction

and splintage. Patients with subluxation of the PIPJ and an associated intra-articular fracture of a size or complexity that would not allow a stable closed reduction were offered surgery. Specifically, fractures of the volar or dorsal aspect of the middle phalangeal base, with ongoing subluxation after initial reduction attempts, pilon fractures involving the PIPJ with articular disruption and subluxation, and sagittal plane injuries with splaying of the base of the middle phalanx, were planned for surgery as stable joint reduction by closed means could not be achieved. Patients were educated preoperatively on the physiotherapy regime (Table 1), the follow-up required, and the need for compliance. Considerable emphasis was placed on the necessary rehabilitation postoperatively, and the need for compliance to facilitate a good outcome (McDonnell, 1999; Spalding, 1995, 2000, 2001). Patients were operated on by the senior author, on the next available operating list.

The device

The *Ligamentotaxor* system applies traction across the PIPJ, allowing movement of the joint while maintaining reduction. The method of force application ensures that a distal distraction force is maintained with angular change at the joint during movement (Schenk, 1986). Maintenance of the distal traction during fracture healing helps reduce the risk of collapse of the fracture fragments. The main aims of this type of fixation are 'adequate reduction' of the PIPJ and restoration of ROM, obviating the need for open surgery.

The device comprises three instruments and a set of disposable components making up the device. The

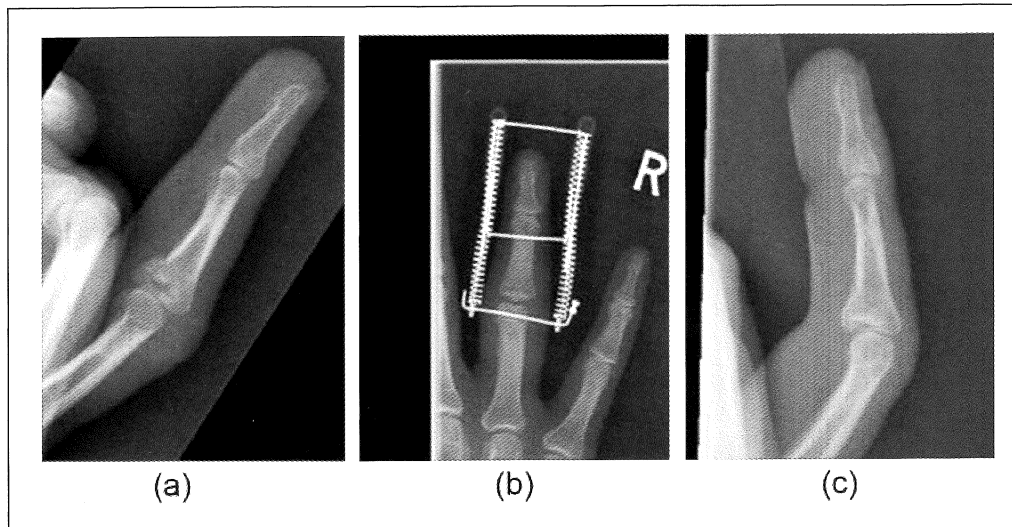


Figure 1. (a) A fracture-subluxation of the PIPJ suitable for dynamic traction with the *Ligamentotaxor*. (b) Postoperative radiograph with the device in situ. (c) Final outcome at 3 months (QuickDASH score = 0).

instruments include a pair of right-angle wire benders, a wire holder, and a radiolucent drill guide allowing parallel wire insertion. The disposable set includes two 1.2mm wires, two coiled springs, and two bushings with a ring at one end to slide perpendicularly onto a transverse wire (Figure 1).

Surgery was performed under general anaesthesia supplemented by ring block anaesthesia. Prior to discharge, patients were seen by a member of the multidisciplinary team (MDT) and encouraged to achieve a good ROM in the affected digit while still numb. The patients were reviewed by a hand therapist at around 48 hours and were subsequently seen by the surgical team after 2 weeks for initial clinical and radiographic assessment. The device remained in situ for between 4 and 6 weeks, unless it was necessary to remove it earlier (e.g. loss of reduction, infection, not tolerated by patient). The wires were removed in the outpatients clinic.

Assessment

Postoperative assessment was performed by a member of the MDT weekly, and by a member of the surgical team fortnightly. Subjective functional assessment of digital and limb function was performed by a member of the surgical team by completion of the QuickDASH questionnaire at final follow-up. Objective measurements of ROM were performed by an extended scope physiotherapist with a specialist interest in hand surgery and rehabilitation, by goniometer measurement of PIPJ motion at 2, 4, and 6 weeks, and at the final follow-up appointment.

Radiographic evaluation was performed at 2 weeks and 6 weeks postoperatively, and at final follow-up (see Figure 2). In addition, further radiographs were taken if changes to the traction or position of the device were made during the postoperative period. Posteroanterior and lateral radiographs were assessed by the senior author and traction was adjusted as necessary, if joint asymmetry of the joint in the coronal plane, or if ongoing subluxation was noted.

Results

A total of 28 patients were included in the study (Table 2). There were 19 men and nine women. The male to female ratio was 2.1:1. The mean age was 33 years (range 18–67). The mean time to surgery was 7 days (range 1–18). Patients were followed up by the surgical and hand therapy team for a minimum of 6 months, with final review at a mean of 22 months (range 6–52). Of the 28 injured fingers there were: five index, two middle, 14 ring, and seven little. Injuries involving the volar aspect of the joint, with associated dorsal subluxations, were commonest (14 patients). Of these, six involved a simple split in the articular surface with joint subluxation and eight were split-depression injuries. There were six injuries involving the dorsal joint with associated volar subluxation, which included four simple articular split fractures and two split-depression fractures. Five patients had fracture patterns in the sagittal plane, and three patients presented with significant pilon-type injuries in the coronal plane involving both dorsal and volar elements of the joint. Pilon fractures represented 13/28 of the injuries, including eight type

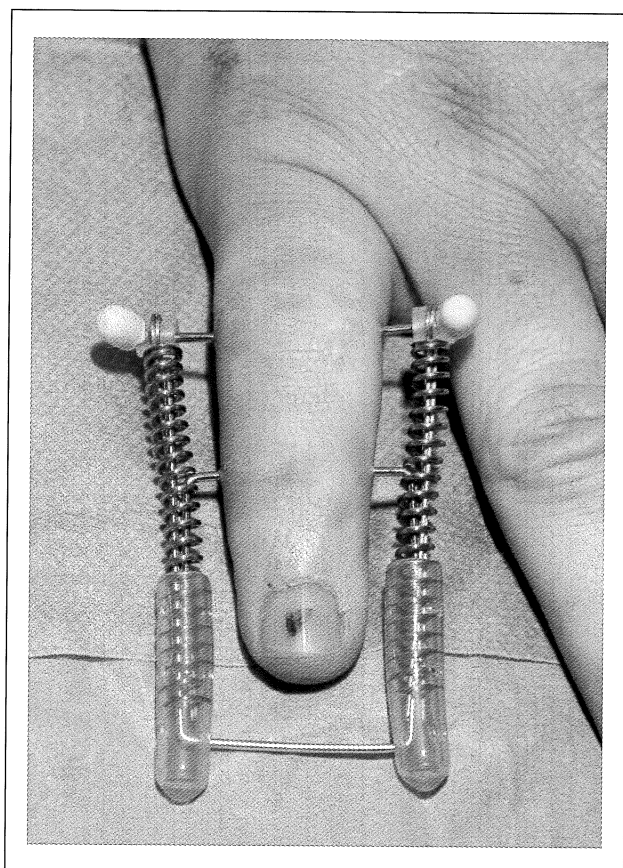


Figure 2. A completed device placed in a little finger PIPJ injury.

Table 2. Demographic data.

	mean	range
Age (mean; range)	33.89	18–67
Female:Male ratio	1:2.11	
Time to surgery (days)	7	1–18
Length of follow-up (months)	22	5–52
Range of PIPJ motion 2 weeks (degrees)	47	28–75
Range of PIPJ motion 4 weeks (degrees)	57	30–90
Range of PIPJ motion 6 weeks (degrees)	70	45–90
Range of motion (final)	85	60–110
Final QuickDASH score (n = 18)	20.3	0–36.4

PIPJ: proximal interphalangeal joint.

1c injuries (volar split depression, two type 2c injuries (dorsal split depression), and three type 5 injuries (volar and dorsal split-depression).

The mean ROM at the PIPJ at 2 weeks was 48° (range 20°–75°). At 4 weeks the mean ROM was 59°

(range 30°–90°), and at 6 weeks the mean ROM was 72° (range 45°–90°). A total of 18 cases were available for final review at a mean of 22 months (range 6–52) postoperatively. At final review, the mean ROM was 85° (range 60°–110°). The six patients with a volar fracture and dorsal subluxation (type 1b) achieved a mean final ROM of 91° (range 70°–110°). Eight patients with type 1c injuries (split-depression on volar side) achieved a mean final ROM of 98° (range 60°–110°). Four patients had type 2b injuries (dorsal articular split fractures), achieving a mean final ROM of 75° (range 60°–95°). Two patients with type 2c injuries (dorsal split-depression) achieved a final mean ROM of 85° and 90°. There were five patients with type 3 injuries, achieving a mean final ROM of 95° (range 70°–110°). Three patients with type 5 injuries (volar and dorsal pilon fractures) involving dorsal and volar elements of the joint, achieved a mean final ROM of 70° (range 60°–85°).

The mean QuickDASH functional outcome score at final follow-up was 20.3 (range 0–36.4). At 6 weeks, all patients demonstrated radiographic evidence of fracture union. At final follow-up, 12 patients had radiographic loss of joint space due to degenerate change. Of these, four patients had marked loss of joint space, which in one case was associated with pain and functional loss, necessitating joint replacement. Widening of the base of the middle phalanx following fracture union was seen in 11/28 patients, of which nine patients had degenerative changes. Eleven cases with phalangeal widening were following injuries in the sagittal plane, while three patients had widening in the coronal plane following injuries in that plane. There were no digits that were significantly deviated due to fracture malunion.

There were a small number of complications during the postoperative period (see Table 3). Two patients had pinsite infections requiring antibiotic treatment, of which one required early removal of the device at 4 weeks. Two patients had extensor lag at the distal interphalangeal joint while the device was in situ, requiring an additional sling to be fitted by the occupational therapist. Four patients experienced irritation or hypergranulation of one or more pinsites, which resolved after removal of the device. In two of these patients the device was removed at 4 weeks. Both of these patients were unhappy with the appearance of the device, and the presence of granulation tissue during the follow-up period. One patient had a loss of reduction at 2 weeks, requiring revision surgery for replacement of the *Ligamentotaxor* device. One patient experienced marked degenerative change after treatment, resulting in PIPJ pain and loss of function, and underwent PIPJ replacement at 6 months.

Table 3. Complications.

Complication	No. of patients
Poor pain control	5
Pinsite irritation	4
Pinsite infection	2
DIPJ extensor lag	2
Loss of reduction requiring revision	1
PIPJ replacement	1

DIPJ: distal interphalangeal joint; PIPJ: proximal interphalangeal joint.

Discussion

Ligamentotaxis for the reduction of articular fractures has been in use since the 1970s (Vidal et al., 1975). Dynamic external fixation and early passive motion for the treatment of PIPJ injuries was first reported by Schenck (1986), and the use of capsuloligamentotaxis as a means of reducing complex injuries of the PIPJ was subsequently reported by Agee (Agee, 1987), who employed a force-coupling device. The 'Pins & Rubbers Traction System' was introduced in 1994 by Suzuki and colleagues who reported good clinical results (Suzuki et al., 1994). This system was also used by De Soras et al. (1997) and Majumder et al. (2003), with comparable outcomes. Hynes and Giddins devised a more rigid system without rubber bands with comparably good outcomes (Hynes and Giddins, 2001). The 'S-Quattro' system (Fahmy, 1990; Khan and Fahmy, 2006) also gained popularity, but has been largely superseded by other devices in recent years. These initial dynamic external fixators provided attractive and novel methods for the treatment of PIPJ injuries, which are known to be challenging to treat. However, outcomes have been variable and many of these devices can be technically difficult to construct and apply. Additionally there is generally no opportunity to readjust position or magnitude of traction in the postoperative period.

Allison was the first to describe the use of springs, with a 'spring dynamic traction device' for the treatment of a series of patients with PIPJ injuries, with reasonable results (Allison, 1996), which was modified by Johnson et al. in 2004. Since that time several similar devices have been available on the market. It is straightforward to construct and the technique can be taught and learned with relative ease.

Previous reports have shown comparable outcomes with the present study (see Table 4). Clinical results of the S-Quattro system reported by Khan and Fahmy (2006) demonstrated a similar range of movement at the PIPJ to those in the present study. Syed et al. (2003) also reported comparable results with a simple dynamic external fixation device

involving two transverse K-wires, the distal wire being bent backwards in a dorsal parabolic curve to link with the more proximal wire. The authors reported a mean ROM of 79° (65°–90°). This is a similar figure to that reported by Suzuki et al. (1994) in their original series treated with pins and rubbers traction. In their series, the patients treated for PIPJ had a final range of flexion between 75° and 95°, with a reported mean of 80° flexion.

In the present series, we have achieved a mean ROM at the PIPJ of 86° (range 65°–110°) using a device that is straightforward to apply, using a reproducible and reliable technique. Furthermore, there were few functional problems following treatment, with only 5/23 patients who completed a QuickDASH outcome score at final follow-up demonstrating any functional deficit. We acknowledge however, that a number of patients did not attend further review appointments after removal of the device and therefore the follow-up time in these patients was limited.

It is worth noting that the clinical results in the present study are comparable with those of Newington et al. (2001), who reported a mean final range of movement of 85° (range 70°–110°) at a mean follow-up time of 16 years (range 14–21). The technique employed by Newington et al. involves passing a temporary Kirschner-wire obliquely across the PIPJ while the joint is held in a reduced position. The wire is subsequently removed several weeks later, in the outpatient setting (Newington et al., 2001). This technique is more straightforward than applying dynamic traction with a *Ligamentotaxor* device, with comparable outcomes, and therefore remains a valuable method for treating less severe fracture subluxation injuries of the PIPJ.

Early mobilization is the rehabilitation method of choice (Fahmy, 1990; Schenk, 1986; Stern et al., 1991). Dynamic traction, which prevents contracture of the ligaments and other peri-articular structures, reduces the incidence of complications associated with immobilization of a digit. Early joint movement enhances fracture healing and joint surface remoulding, facilitates joint nutrition and hence cartilage remodelling, reduces swelling, limits tendon adherence, and prevents subsequent joint stiffness (Buckwalter, 1996; Khan and Fahmy, 2006; Stern, 1991). Light hand function is encouraged, while heavy tasks and further local trauma must be avoided.

Compliance with therapy and regular attendance at outpatient clinic appointments must be ensured, to allow for pinsite care, early intensive rehabilitation, and regular plain radiographs assessing maintenance of reduction and progression of healing. In addition, adequate analgesia is essential to allow early effective rehabilitation. Unaffected joints can be

Table 4. Previous studies reporting outcomes of dynamic external fixation devices for PIPJ injuries.

Study	No. of patients	Follow-up (months)	Final ROM (degrees)	Complications
MacFarlane et al., 2015	29	22	10–86	Pinsite infection ×2, loss of reduction ×1, PIPJ replacement ×1
Johnson et al., 2004	10	19	8–84	Pinsite infection ×2; additional wires required ×2
Syed et al., 2003	8	26	9–79	Disassembly of device ×2
Hynes and Giddins, 2001	8	20	11–86	Pinsite infection ×2; pain ×3
De Soras et al., 1997	11	9.7	10–84	Osteitis ×1, pinsite inflammation ×5
Allison, 1996	14	12	11–84	Redislocation ×1; OA ×1
Khan and Fahmy, 1996	81	10.5	10–92	Pain ×9

OA: osteoarthritis; PIPJ: proximal interphalangeal joint; ROM: range of motion.

fully, actively and passively mobilized. Additional splintage (e.g. night time splint, or slings in the event of swan neck deformity, or extension lag in the post-operative period) can be applied around the frame as required. We recommend a fully integrated multidisciplinary approach to treating this group of patients. In addition to their role in the postoperative period, multidisciplinary team members have an important role preoperatively. Our experience highlighted several cases where patients were not fully prepared for the implications of the surgery, and have been disturbed postoperatively by the appearance of the frame, or skin irritation caused by the frame, or by granulation tissue. It is well documented that patients respond more effectively, are less anxious, and experience less pain postoperatively if they are prepared and aware of what to expect (McDonnell, 1999; Spalding, 1995, 2000, 2001).

A number of clear limitations to the present study exist: the lack of a control group has meant that comparison with other methods of treatment is limited; and the loss of several patients to follow-up has resulted in a range in follow-up times and therefore several late complications may have been missed.

Despite these issues, we have found the *Ligamentotaxor* to be a safe and effective device in the management of intra-articular PIPJ injuries. It has a number of practical advantages over other devices in common use, and appears to be of comparable efficacy next to other results for other devices reported in the literature. Although the device does not provide improved results over simpler techniques for the treatment of fracture subluxations of the PIPJ, such as temporary K-wire stabilization, it provides an effective surgical option for complex injuries with articular surface disruption and comminution requiring dynamic traction. In addition, the ability for the device to be altered in the postoperative period is a particular advantage. We recommend consideration of the *Ligamentotaxor* in those fractures and fracture-subluxations involving the PIPJ requiring dynamic

traction, which are not treatable by conservative measures.

Conflict of interests

None declared.

Funding

This research received no specific grant from any funding agency in the public, commercial, or not-for-profit sectors.

References

- Agee JM. Unstable fracture dislocations of the proximal interphalangeal joint. Treatment with a force couple splint. *Clin Orthop Relat Res.* 1987, 214: 101–12.
- Allison D. Fractures of the base of the middle phalanx treated by a dynamic external fixation device. *J Hand Surg Br.* 1996, 21: 305–10.
- Buckwalter JA. Effects of early motion on healing of musculoskeletal tissues. *Hand Clin.* 1996, 12: 13–24.
- Deitch M, Kieffhaber T, Comisar B, Stern P. Dorsal fracture dislocations of the proximal interphalangeal joint: surgical complications and long-term results. *J Hand Surg Am.* 1999, 24: 914–23.
- De Soras X, De Mourgues P, Guinford D, Moutet F. Pins and rubber traction system. *J Hand Surg Br.* 1997, 22: 730–5.
- Ellis SJ, Cheng R, Prokopis P et al. Treatment of proximal interphalangeal dorsal fracture-dislocations injuries with dynamic external fixation: a pins and rubber band system. *J Hand Surg Am.* 2007, 32: 1242–50.
- Fahmy N. The Stockport Serpentine Spring System for the treatment of displaced comminuted intra-articular phalangeal fractures. *J Hand Surg Br.* 1990, 15: 303–11.
- Grant A, Berger S, Tham S. Internal fixation of unstable fracture dislocations of the proximal interphalangeal joint. *J Hand Surg Eur.* 2005, 30: 492–8.
- Hynes M, Giddins G. Dynamic external fixation for pilon fractures of the interphalangeal joints. *J Hand Surg Br.* 2001, 26: 122–4.
- Johnson D, Tiernan E, Richards A, Cole R. Dynamic fixation for complex intra-articular phalangeal fractures. *J Hand Surg Br.* 2004, 29: 76–81.

- Khan W, Fahmy N. The S-Quattro in the management of acute intra-articular phalangeal fractures of the hand. *J Hand Surg Br.* 2006, 31: 79–92.
- Körting O, Facca S, Diaconu M, Liverneaux P. Treatment of complex proximal interphalangeal joint fractures using a new dynamic external fixator: 15 cases. *Chir Main.* 2009, 28: 153–7.
- Majumder S, Peck F, Watson J, Lees V. Lessons learned from the management of complex intra-articular fractures at the base of the middle phalanges of fingers. *J Hand Surg Br.* 2003, 28: 559–65.
- McDonnell A. A systematic review to determine the effectiveness of preparatory information in improving the outcomes of adult patients undergoing invasive procedures. *Clin Eff Nurs.* 1999, 3: 4–11.
- Newington D, Davis T, Barton N. The treatment of dorsal fracture-dislocation of the proximal interphalangeal joint by closed reduction and Kirschner wire fixation: a 16-year follow up. *J Hand Surg Br.* 2001, 26: 537–40.
- Schenk RR. Dynamic traction and early passive movement for fracture of the proximal interphalangeal joint. *J Hand Surg Am.* 1986, 11: 850–8.
- Seno N, Hashizume H, Inoue H, Imatani J, Morito Y. Fractures of the base of the middle phalanx of the finger. Classification, management and long-term results. *J Bone Joint Surg Br.* 1997, 22: 758–63.
- Spalding N. A comparative study on the effectiveness of a pre-operative education programme for total hip replacement patients. *Br J Occ Ther.* 1995, 58: 526–31.
- Spalding N. The empowerment of clients through pre-operative education. *Br J Occ Ther.* 2000, 63: 148–54.
- Spalding N. Clients views of pre-operative education before hip replacement. *Br J Occ Ther Rehab.* 2001, 8: 130–5.
- Stern PJ, Roman RJ, Kiefhaber TR, McDonough JJ. Pilon fractures of the proximal interphalangeal joint. *J Hand Surg Am.* 1991; 16: 844–50.
- Suzuki Y, Meatsunaga T, Sato S, Yokoi T. The pins and rubbers traction system for treatment of comminuted intra-articular fractures and fracture-dislocations in the hand. *J Hand Surg Br.* 1994, 19: 98–107.
- Syed AA, Agarwal M, Boome R. Dynamic external fixator for pilon fractures of the proximal interphalangeal joints: a simple fixator for a complex fracture. *J Hand Surg Br.* 2003, 28: 137–41.
- Vidal J, Buscayret C, Connes H. Treatment of articular fractures by 'ligamentotaxis' with external fixation. In: Brooker AF, Edwards CC (Eds.) *External fixation – the current state of the art.* Baltimore, Williams & Jenkins, 1975: 75–81.

Reference to trade names, commercial organizations and their products and the inclusion of advertisements in the journal does not imply endorsements by SAGE, its society publishing partners, the editors, or the editorial board. To the extent permitted under applicable law neither SAGE nor the associated society assumes nor shall have any liability for injury and/or damage to persons or property and/or death directly or indirectly arising out of or related to any of the material in this journal. Please promptly inform the editors of any errors.

For more information, please contact Manuela Brun
Tel. +44 (0)207 324 8523 Email. Manuela.brun@sagepub.co.uk
Website: <http://www.sagepub.co.uk/journals.nav>

Reprinted by:

 **SAGE** Los Angeles • London • New Delhi • Singapore
www.sagepublications.com